

Japanese Doctors Confirm Rare Heart Condition After COVID Shot

By [John-Michael Dumais](#)

Global Research, July 23, 2024

[Children's Health Defense](#) 22 July 2024

Region: [Asia](#)

Theme: [Science and Medicine](#)

A case study from Japan has documented the first known biopsy-proven instance of [inflammatory dilated cardiomyopathy](#) (iDCM) — a condition where the heart becomes enlarged and weakened due to inflammation — following COVID-19 vaccination.

Doctors at Narita-Tomisato Tokushukai Hospital in Chiba, Japan, used an [endomyocardial biopsy](#) to diagnose iDCM in a 78-year-old woman who developed heart problems after receiving her third [COVID-19](#) vaccine dose.

The patient had previously received two doses of the [Pfizer-BioNTech](#) BNT162b2 mRNA vaccine, followed by a [Moderna mRNA-1273 booster](#).

The case, reported on July 1 in a peer-reviewed open-access article in the journal [ESC Heart Failure](#), marks a significant advancement in understanding potential cardiac complications related to [COVID-19 vaccines](#).

By using tissue analysis, doctors were able to more definitively link the [heart condition](#) to the [vaccination](#), distinguishing it from other possible causes.

“While such severe reactions remain extremely rare, this case demonstrates the value of advanced diagnostic techniques in identifying and understanding vaccine-related side effects,” the doctors wrote.

The patient was successfully treated with a [corticosteroid](#), which improved her condition significantly but not completely.

This outcome underscores the importance of prompt medical attention and accurate diagnosis for any unusual symptoms following vaccination.

“Severe cases [can be fatal](#) if left untreated,” the doctors wrote.

[Dr. Peter McCullough](#) agreed, telling [The Defender](#) that his [January paper](#) with [Jessica Rose, Ph.D.](#), and [Nicolas Hulscher](#) showed that in thousands of [vaccine-associated myocarditis](#) cases, the mortality rate is 2.9%.

McCullough said the Japanese paper is important because it applies to heart failure occurring months to years after COVID-19 vaccination. For patients with similar symptoms, doctors should seriously consider the possibility that the COVID-19 vaccine might have caused the damage, he said.

Brian Hooker, Ph.D., chief scientific officer at [Children’s Health Defense](#), told The Defender the case study was “very robust.”

“They rule out cardiac infection as well as chronic myocarditis via autoimmunity in order to deduce a diagnosis of vaccine-associated myocarditis,” Hooker said.

Patient Was ‘in Acute Heart Failure’

The patient, with no prior history of heart disease, experienced palpitations and shortness of breath on the fourth day after receiving her third COVID-19 vaccine dose. Her symptoms gradually worsened and she was admitted to the hospital 11 days post-vaccination.

“By the time she was admitted to our hospital, she was in acute heart failure,” the doctors explained.

Upon examination, they noted several concerning signs:

- Rapid heartbeat of 120 beats per minute.
- Swollen neck veins and leg edema.
- Abnormal heart sounds, including a gallop rhythm and heart murmur.
- Low blood oxygen levels.

Diagnostic tests indicated cardiac dysfunction. An electrocardiogram (EKG) showed an abnormally rapid heart rate with disrupted electrical conduction patterns in both the right and left sides of the heart.

Blood tests revealed elevated levels of [cardiac troponin I](#) and [brain natriuretic peptide](#), both markers of myocardial stress and damage. An EKG demonstrated severely reduced left ventricular function, with an [ejection fraction](#) of only 20%.

To rule out coronary artery disease, the medical team performed an X-ray test called [coronary angiography](#), which showed no significant obstructions.

The constellation of symptoms and test results led the physicians to diagnose iDCM, potentially associated with the recent COVID-19 vaccination. To establish a definitive diagnosis, they proceeded with an endomyocardial biopsy.

Responding to a tweet about the Japanese study, Lori Petersen, injured by the Pfizer vaccine, posted this on X (formerly Twitter) on Thursday:

About to get my second echocardiogram due to this vaccine! 41 left ventricle no longer pumping as it should. 2 years later I’m getting another because I’m still suffering shortness of breath, chest pain, and now waking up gasping for air. Hoping my ventricle isn’t any worse!...

— Lori Petersen (@LoriLee13Peters) [July 19, 2024](#)

Key Findings

The endomyocardial biopsy provided crucial insights into the patient’s condition. Under the microscope, doctors observed signs of inflammation in the heart tissue, confirming the

diagnosis of iDCM. These signs included:

- Enlarged heart muscle cells.
- Scarring between the cells.
- Clusters of inflammatory cells, primarily [macrophages](#) and T-lymphocytes, or [T-cells](#).

The biopsy also revealed increased levels of [tenascin-C](#), a protein that is typically elevated during active heart inflammation. This suggested the patient's condition was in an active stage and potentially treatable.

A cardiac MRI, another advanced imaging technique, showed additional signs of heart damage. It revealed an enlarged left ventricle and a pattern of scarring in the heart muscle wall that's often seen in non-infectious causes of heart inflammation.

"The biopsy allowed us to directly observe the inflammatory process in the heart tissue, providing a level of certainty we haven't had in previous cases of suspected vaccine-related heart issues," the doctors wrote.

They emphasized how this case differs from previously reported vaccine-related heart issues.

"Most reported cases of heart inflammation after COVID-19 vaccination have been [myocarditis in young males](#). This case of iDCM in an older female patient expands our understanding of potential cardiac complications."

The detailed findings allowed doctors to distinguish this case from other types of heart problems and strongly suggested a link to the recent COVID-19 vaccination.

Follow-up Examinations at Six Months Showed 'Significant Improvements'

After confirming the diagnosis of iDCM through biopsy, doctors initiated a targeted treatment plan involving the oral corticosteroid [prednisolone](#) to reduce inflammation in the heart.

The medical team also administered standard heart failure medications, including:

- [Enalapril](#), to help relax blood vessels.
- [Spironolactone](#), a diuretic that also has anti-inflammatory properties.
- [Dapagliflozin](#), a newer medication shown to be beneficial in heart failure.

The patient's condition improved steadily following treatment. After 16 days in the hospital, she was discharged with a reduced dose of prednisolone.

Follow-up examinations at six months showed significant improvements in the patient's heart function. "The echocardiogram revealed a dramatic recovery in the heart's pumping ability," the doctors wrote. "The left ventricular ejection fraction improved from 20% to 56%, which is within the normal range."

The follow-up cardiac MRI confirmed the reversal of the earlier abnormalities, showing a reduction in heart size and improved function. Additionally, a repeat biopsy demonstrated a marked decrease in inflammation within the heart tissue.

The patient remained stable without any recurrence of symptoms during the one-year follow-up period.

Hooker's assessment of the patient's recovery was more restrained. "This sounds more like chronic myocarditis (scarring and enlarged heart) rather than acute myocarditis where the chance of a full recovery is about 66% within 2-3 months."

Hooker pointed out that scarring of the heart is permanent and in this case, the heart's ejection fraction had not completely recovered by the six-month follow-up appointment.

Vigilance and Investigation of Potential Vaccine-related Adverse Events Needed

The case study provides new insights into the spectrum of cardiac complications potentially linked to COVID-19 vaccines. The researchers emphasized several key points in their discussion.

Current understanding of COVID-19 vaccine-associated myocarditis primarily involves cases in young males, often occurring after the second vaccine dose.

Hooker noted that the [young males have the highest risk of heart damage](#) from the mRNA vaccines.

These myocarditis cases typically show an abundance of lymphocytes, a type of white blood cell, infiltrating the heart tissue.. But this case diverges from the typical vaccine-associated myocarditis profile in several ways:

- The patient was an older female.
- The complication occurred after a third dose of a different COVID-19 vaccine.
- The diagnosis was specifically iDCM.

The biopsy findings revealed a mix of macrophages and [T-lymphocytes](#) in the heart tissue — immune system cells designed to rid the body of infection and disease — along with cardiac [microthrombi](#) (tiny blood clots).

This pattern differs from previously reported vaccine-associated myocarditis cases and other types of vaccine-related heart inflammation. This underscores the complexity of immune responses to vaccines, the doctors wrote.

The researchers stressed the importance of considering iDCM in patients who present with heart failure symptoms following COVID-19 vaccination, particularly when the clinical picture doesn't match typical myocarditis.

"Clinicians should not hesitate to perform EMB [endomyocardial biopsy] on patients presenting with the DCM [dilated cardiomyopathy] phenotype following SARS-CoV-2 immunization," the doctors emphasized.

McCullough said that he considers all vaccine recipients to have potentially suffered cardiac damage. "In my clinical practice ... I take a tiered approach with history, exam, ECG, laboratories and in selected cases, [echocardiography](#)/cardiac MRI."

The Japanese team acknowledged that while such severe reactions remain extremely rare,

this case highlights the need for continued vigilance and thorough investigation of potential vaccine-related adverse events.

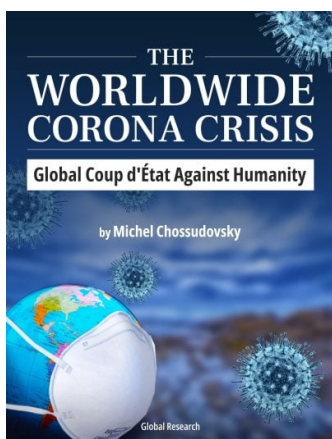
*

Click the share button below to email/forward this article to your friends and colleagues. Follow us on [Instagram](#) and [Twitter](#) and subscribe to our [Telegram Channel](#). Feel free to repost and share widely Global Research articles.

[Spread the Truth, Refer a Friend to Global Research](#)

John-Michael Dumais is a news editor for The Defender. He has been a writer and community organizer on a variety of issues, including the death penalty, war, health freedom and all things related to the COVID-19 pandemic.

Featured image is from CHD



The Worldwide Corona Crisis, Global Coup d'Etat Against Humanity

by Michel Chossudovsky

Michel Chossudovsky reviews in detail how this insidious project “destroys people’s lives”. He provides a comprehensive analysis of everything you need to know about the “pandemic” — from the medical dimensions to the economic and social repercussions, political underpinnings, and mental and psychological impacts.

“My objective as an author is to inform people worldwide and refute the official narrative which has been used as a justification to destabilize the economic and social fabric of entire countries, followed by the imposition of the “deadly” COVID-19 “vaccine”. This crisis affects humanity in its entirety: almost 8 billion people. We stand in solidarity with our fellow human beings and our children worldwide. Truth is a powerful instrument.”

Reviews

This is an in-depth resource of great interest if it is the wider perspective you are motivated to understand a little better, the author is very knowledgeable about geopolitics and this comes out in the way Covid is contextualized. —Dr. Mike Yeadon

In this war against humanity in which we find ourselves, in this singular, irregular and massive assault against liberty and the goodness of people, Chossudovsky’s book is a rock

upon which to sustain our fight. -Dr. Emanuel Garcia

In fifteen concise science-based chapters, Michel traces the false covid pandemic, explaining how a PCR test, producing up to 97% proven false positives, combined with a relentless 24/7 fear campaign, was able to create a worldwide panic-laden "plandemic"; that this plandemic would never have been possible without the infamous DNA-modifying Polymerase Chain Reaction test - which to this day is being pushed on a majority of innocent people who have no clue. His conclusions are evidenced by renown scientists. —Peter Koenig

Professor Chossudovsky exposes the truth that "there is no causal relationship between the virus and economic variables." In other words, it was not COVID-19 but, rather, the deliberate implementation of the illogical, scientifically baseless lockdowns that caused the shutdown of the global economy. -David Skripac

A reading of Chossudovsky's book provides a comprehensive lesson in how there is a global coup d'état under way called "The Great Reset" that if not resisted and defeated by freedom loving people everywhere will result in a dystopian future not yet imagined. Pass on this free gift from Professor Chossudovsky before it's too late. You will not find so much valuable information and analysis in one place. -Edward Curtin

ISBN: 978-0-9879389-3-0, Year: 2022, PDF Ebook, Pages: 164, 15 Chapters

Price: ~~\$11.50~~ FREE COPY! [Click here \(docsend\) and download.](#)

[You may also access the online version of the e-Book by clicking here.](#)

We encourage you to support the eBook project by making a donation through Global Research's [DonorBox "Worldwide Corona Crisis" Campaign Page.](#)

The original source of this article is [Children's Health Defense](#)
Copyright © [John-Michael Dumais](#), [Children's Health Defense](#), 2024

[Comment on Global Research Articles on our Facebook page](#)

[Become a Member of Global Research](#)

Articles by: [John-Michael
Dumais](#)

Disclaimer: The contents of this article are of sole responsibility of the author(s). The Centre for Research on Globalization will not be responsible for any inaccurate or incorrect statement in this article. The Centre of Research on Globalization grants permission to cross-post Global Research articles on community internet sites as long the source and copyright are acknowledged together with a hyperlink to the original Global Research article. For publication of Global Research articles in print or other forms including commercial internet sites, contact: publications@globalresearch.ca
www.globalresearch.ca contains copyrighted material the use of which has not always been specifically authorized by the copyright owner. We are making such material available to our readers under the provisions of "fair use" in an effort to advance

a better understanding of political, economic and social issues. The material on this site is distributed without profit to those who have expressed a prior interest in receiving it for research and educational purposes. If you wish to use copyrighted material for purposes other than "fair use" you must request permission from the copyright owner.

For media inquiries: publications@globalresearch.ca