

Erythema Multiforme After Pfizer and Moderna COVID-19 mRNA Vaccines

14 papers reviewed with photographs of 20 confirmed cases - mRNA Injury to the Immune system

By [Dr. William Makis](#)

Theme: [Science and Medicine](#)

Global Research, November 13, 2023

[COVID Intel](#)

All Global Research articles can be read in 51 languages by activating the Translate Website button below the author's name.

To receive Global Research's Daily Newsletter (selected articles), [click here](#).

Click the share button above to email/forward this article to your friends and colleagues. Follow us on [Instagram](#) and [Twitter](#) and subscribe to our [Telegram Channel](#). Feel free to repost and share widely Global Research articles.

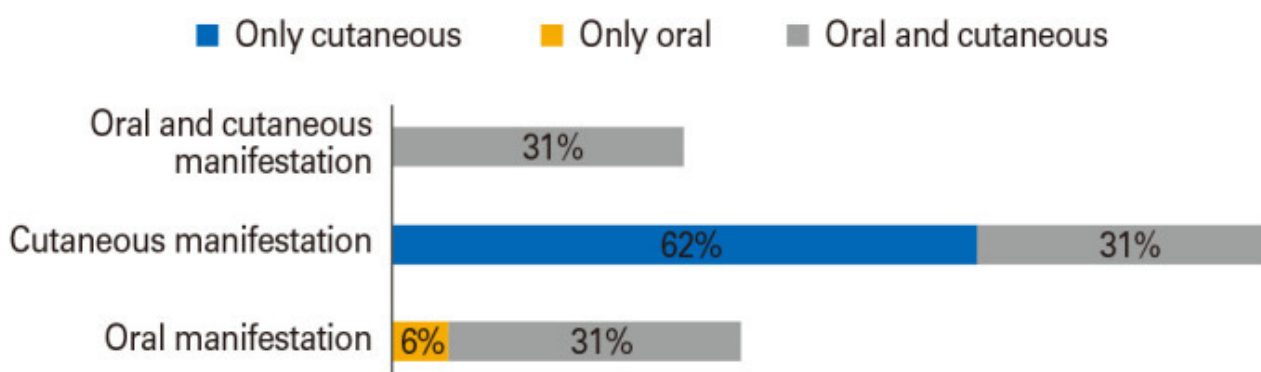
Papers Reviewed

- [2023 Jun \(Murata et al\)](#) - Erythema Multiforme Induced by Zonisamide and Triggered by the First Dose of COVID-19 Vaccine (Pfizer-BioNTech)
- [2023 Apr \(Yousefian et al\)](#) - Occurrence of erythema multiforme following COVID-19 vaccination: a review
- [2023 Feb \(Karatas et al\)](#) - Erythema multiforme reactions after Pfizer/BioNTech (BNT162b2) and Moderna (mRNA-1273) COVID-19 vaccination: A case series
- [2022 Nov \(Fadul et al\)](#) - Sever erythema multiforme post-COVID-19 moderna vaccine: Case report and literature review
- [2022 Apr \(Castillo et al\)](#) - Erythema multiforme after the third dose of mRNA-1273 (behind paywall)
- [2022 Mar \(Petruzzi et al\)](#) - Oral erythema multiforme after Pfizer-BioNTech COVID-19 vaccination: a report of four cases
- [2021 Nov \(Burlando et al\)](#) - Cutaneous reactions to COVID-19 vaccine at the dermatology primary care
- [2021 Oct \(Kim et al\)](#) - Generalized erythema multiforme-like skin rash following the first dose of COVID-19 vaccine (Pfizer-BioNTech)
- [2021 Oct \(Wunderlich et al\)](#) - Erythema exsudativum multiforme infolge einer COVID-19-Impfung (BNT162b2)
- [2021 Oct \(Saibene et al\)](#) - Erythema Multiforme Major following SARS-CoV-2 vaccine
- [2021 Oct \(Majenka et al\)](#) - Multiforme Erytheme nach COVID-19-mRNA-Impfung
- [2021 Sep \(Bonino et al\)](#) - Atypical erythema multiforme related to BNT162b2 (Pfizer-BioNTech) COVID-19 vaccine

- [2021 Sep \(Borg et al\)](#) – Pfizer-BioNTech SARS-CoV-2 mRNA vaccine-associated erythema multiforme
- [2021 Sep \(Scharf et al\)](#) – Nevocentric erythema multiforme after SARS-COV-2 vaccine

[2023 Apr \(Yousefian et al\)](#) - Occurrence of erythema multiforme following COVID-19 vaccination: a review

- Erythema multiforme (EM) is among the oral mucocutaneous side effects of COVID-19 vaccines
- Review: 90 patients with Erythema Multiforme (EM) as a side effect of COVID-19 vaccination across several studies
- EM is a skin inflammatory condition, typically caused by infections (herpes simplex virus and mycoplasma), medications and internal diseases
- to date: 984 cases of EM due to vaccinations (mumps, measles, Hep.B)
- EM minor: skin lesions < 10% of body surface with minimal or no mucosal
- EM major: skin lesions > 10% body surface with mucosal involvement
- Oral EM: oral mucosal ulcers without any skin lesions
- In this review of 90 EM patients after COVID-19 Vaccines:
 - mean age 51, women 2x than men
 - 79% of the vaccines were mRNA vaccines 47% Pfizer, 32% Moderna
 - 45% developed EM less than 3 days after jab
- EM is an acute self-limiting reaction caused by exaggerated immune response, which is characterized by targetoid skin lesions that may be associated with mucosal involvement as well.
- mRNA elicits cellular immune response to antigens through CD4 type 1 T-helper cells, and induce the release of interferon IFN-gamma and eventual activation of autoreactive system in genetically susceptible individuals.
- Treat: Corticosteroids are prescribed topically, orally (30-90 mg prednisolone daily) or intravenously (0.5-1 mg/kg body weight methyl prednisolone every 8 hours) for more severe cases

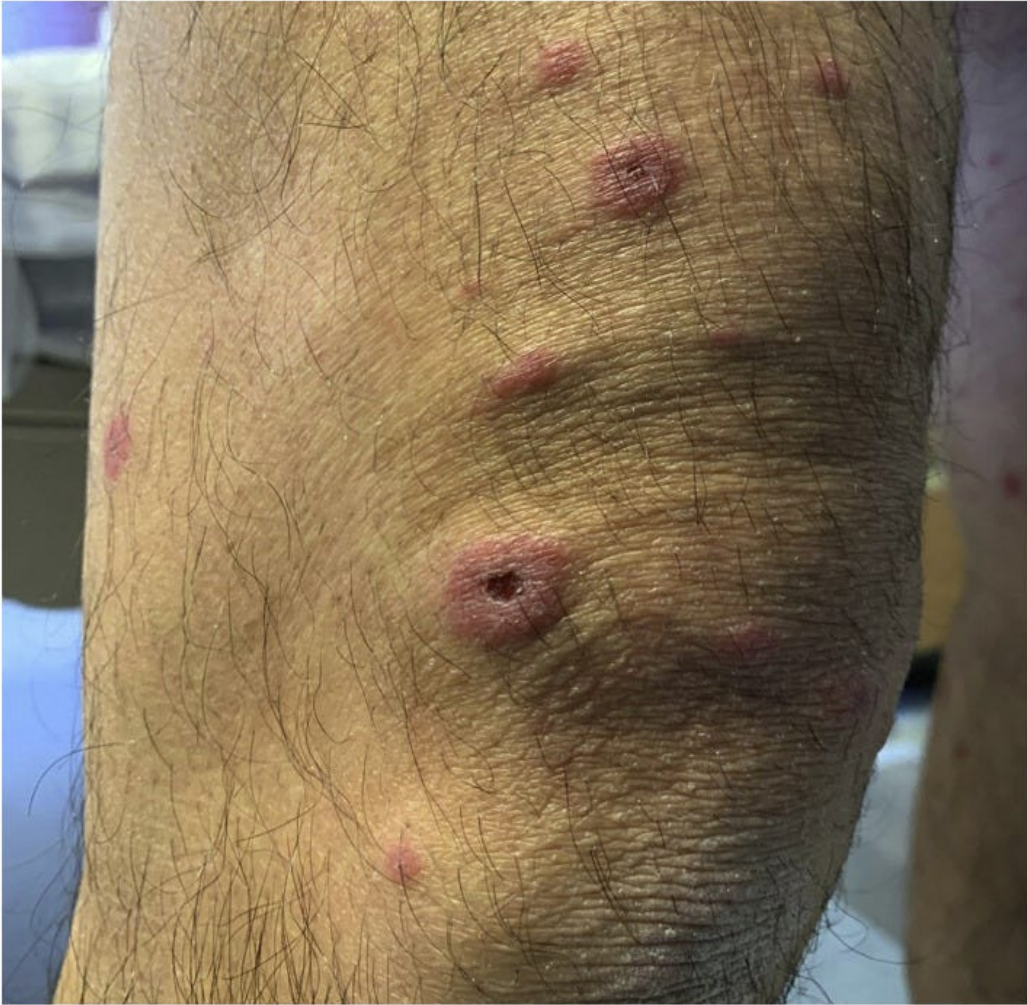

[2023 Feb \(Karatat et al\)](#) - Erythema multiforme reactions after Pfizer/BioNTech (BNT162b2) and Moderna (mRNA-1273) COVID-19 vaccination: A case series

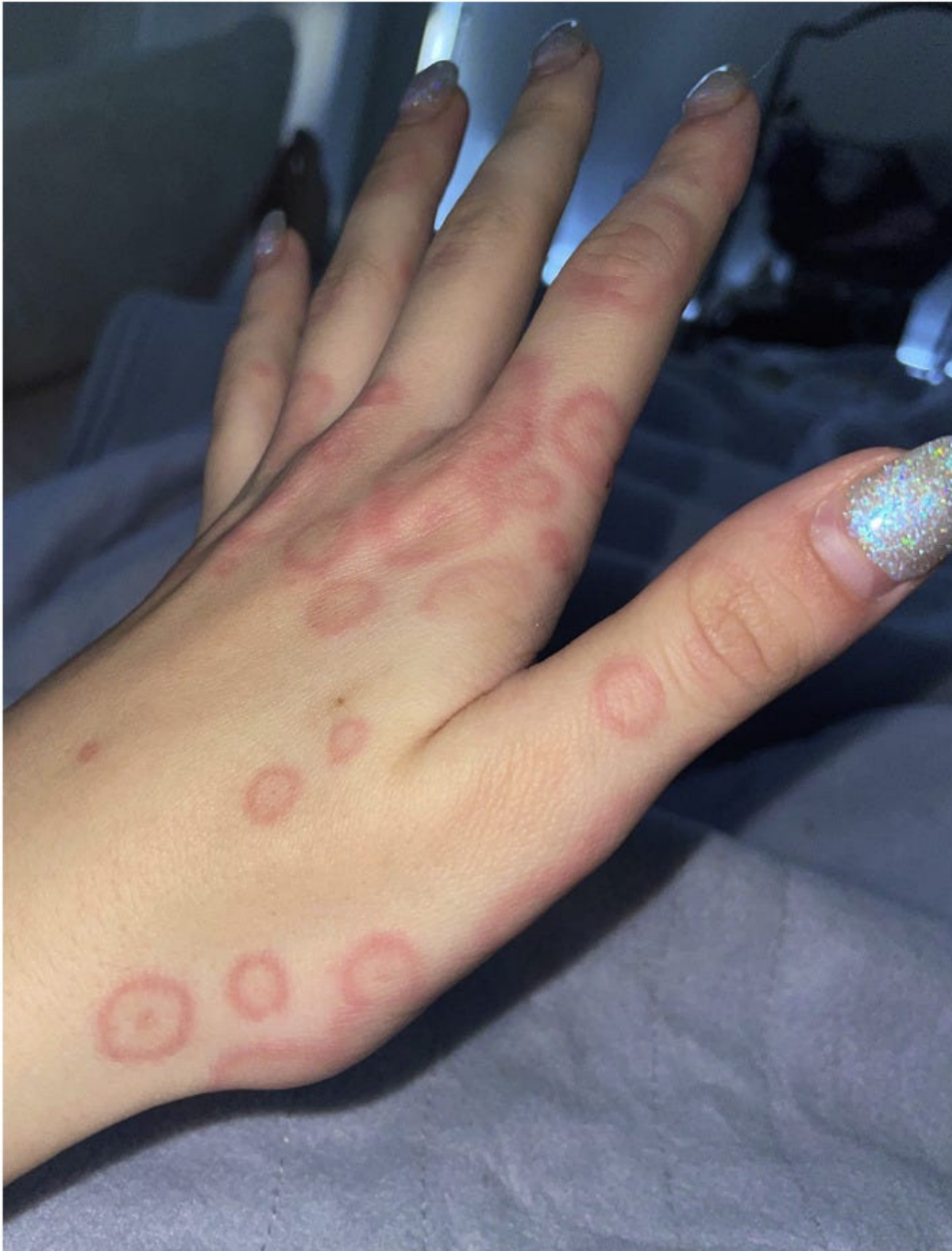- CASE 1: 61M had 1st dose Moderna 10 days before onset of symptoms
- Physical examination (P/E) revealed scattered, non-tender, erythematous, targetoid plaques on the face, trunk, and extremities, including the palms and soles
- also had bilateral conjunctival erythema with multiple vesicles and erosions in

the oral mucosa

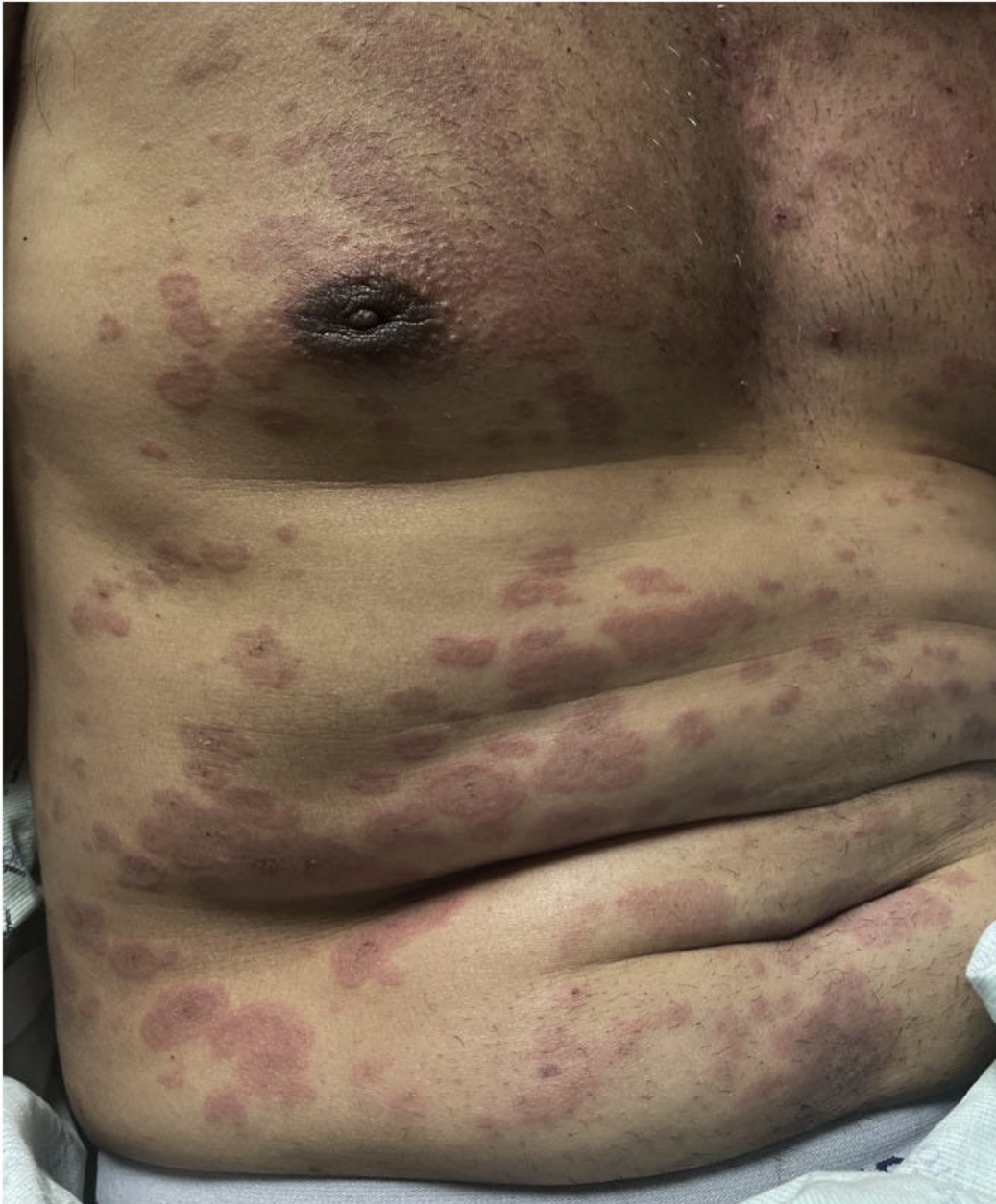- Diagnosis; EM major with extensive oral and nasal involvement



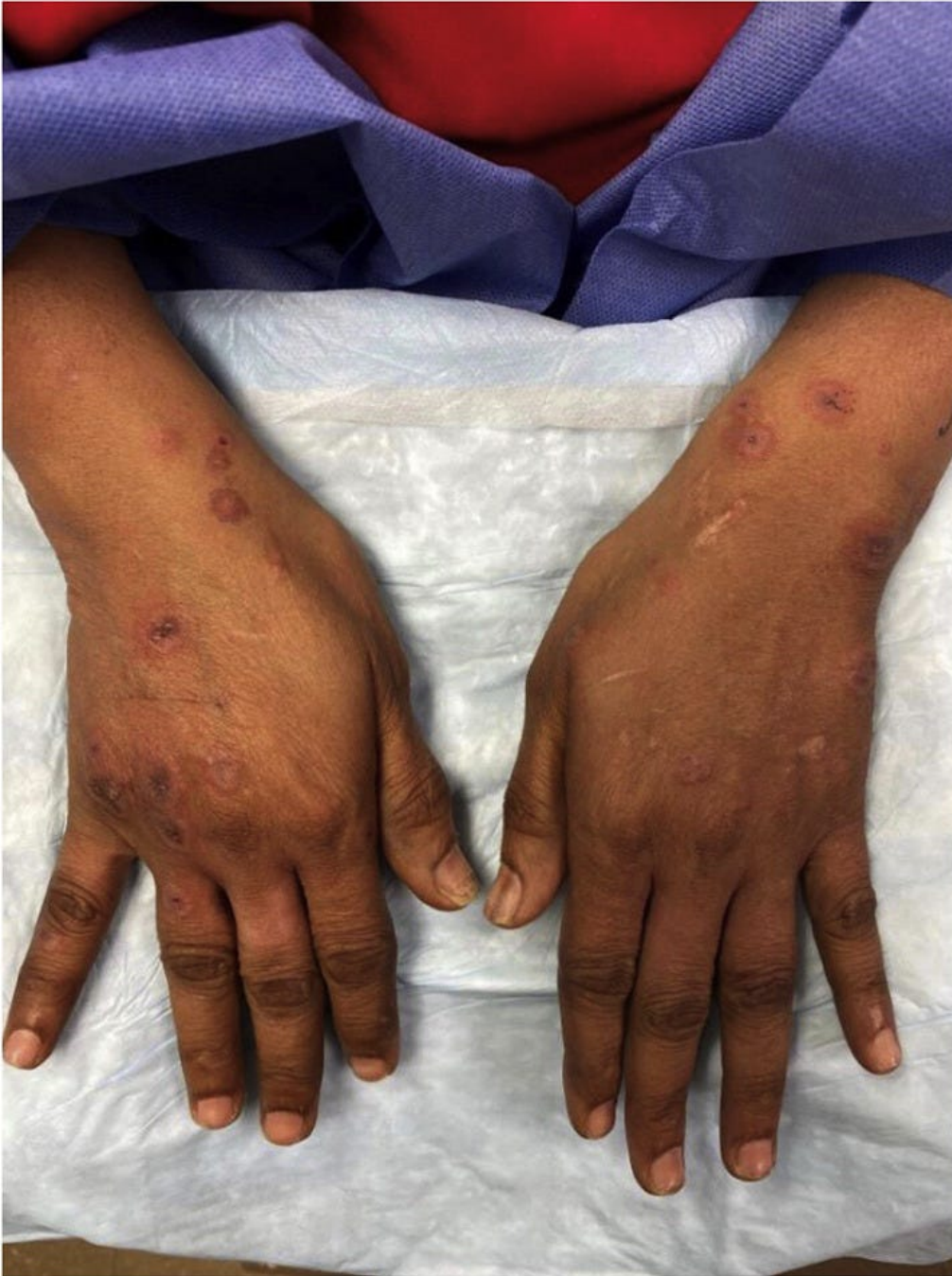- CASE 2: 21F had 2nd dose of Pfizer mRNA 3 days prior
- Presented with rash on hands and feet, swelling and joint discomfort
- She was diagnosed with EM, put on steroids and rash resolved



- CASE 3: 50M had 2nd Pfizer mRNA dose 5 days prior onset of symptoms
- Presented with worsening rash and pruritus for 4 days.
- had erythematous targetoid plaques on trunk and extremities and hemorrhagic crusts on oral mucosa
- was diagnosed with EM and put on prednisone taper and also topical steroid



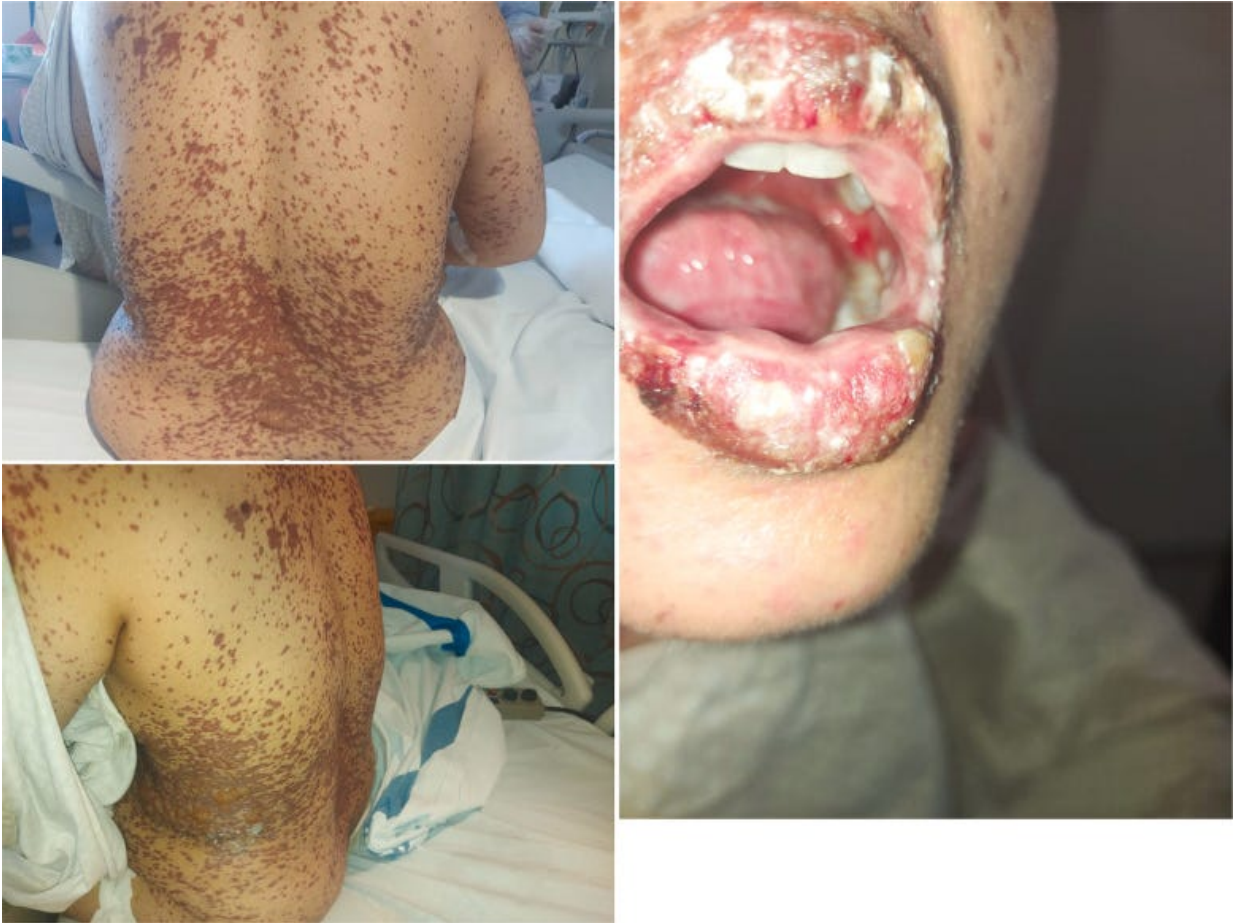- CASE 4: 53F had 2nd Moderna mRNA dose 2 days prior to onset
- presented with a 3 week history of rash and pruritus on hands, arms and legs
- P/E: erythematous targetoid plaques on hands and extremities, no mucosal involvement.
- Diagnosed with EM and treated with topical steroid.



- pathogenic mechanism of EM after infection is thought to be a cell-mediated immune reaction with activation of T helper cells and cytokine production, resulting in a robust mucocutaneous inflammatory response.
- The mechanism of EM after vaccination is not entirely clear, but it is likely to be a similar mechanism

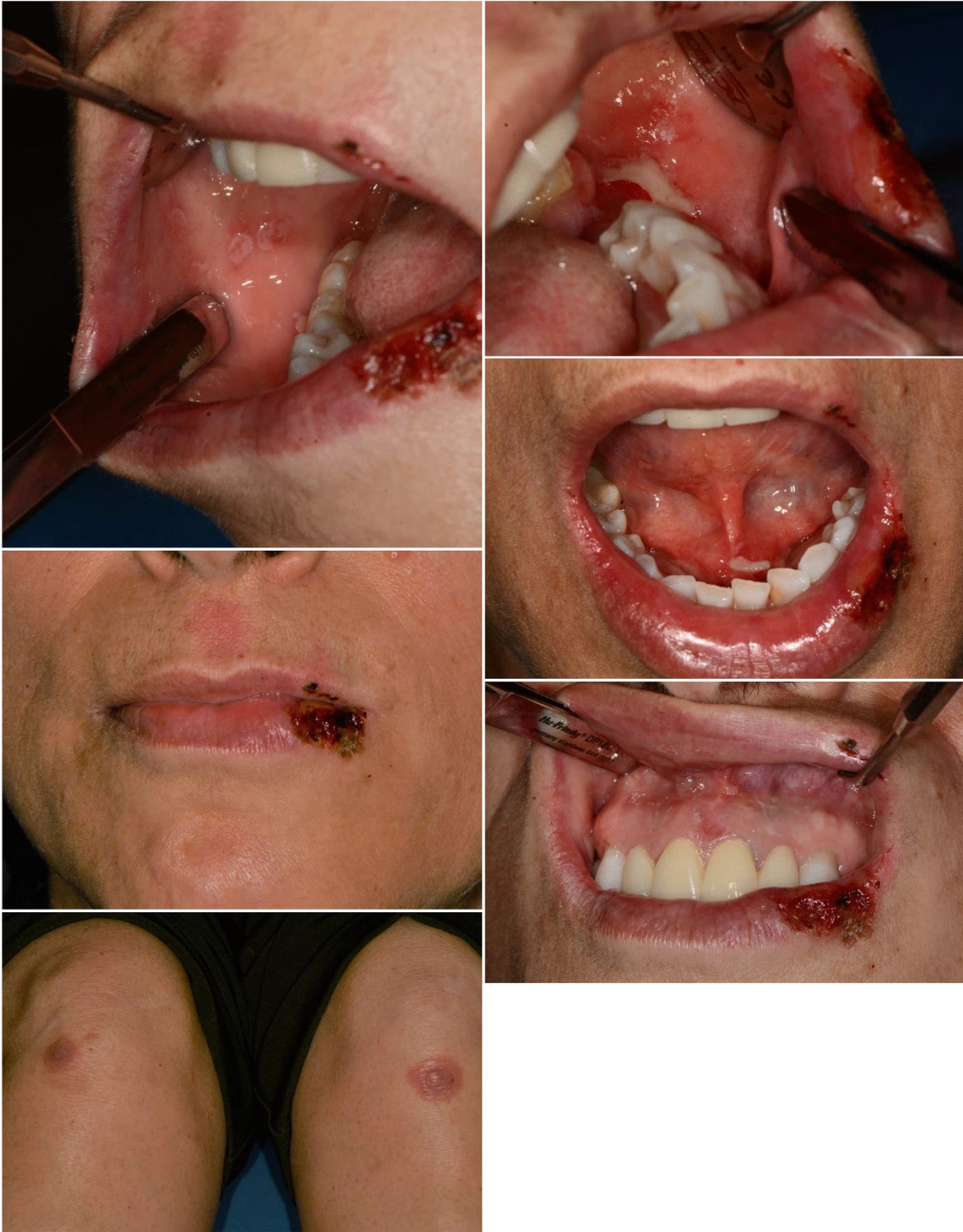2022 Nov (Fadul et al) - Sever erythema multiforme post-COVID-19 Moderna vaccine: Case report and literature review

- 36F woman had 1st Moderna mRNA 24 hours prior to onset
- presented with sore throat, painful mouth ulcers, bilateral red and itchy eyes and itchy skin lesions that started on her chest, back and genital area and quickly spread to the rest of her body, becoming intensely itchy

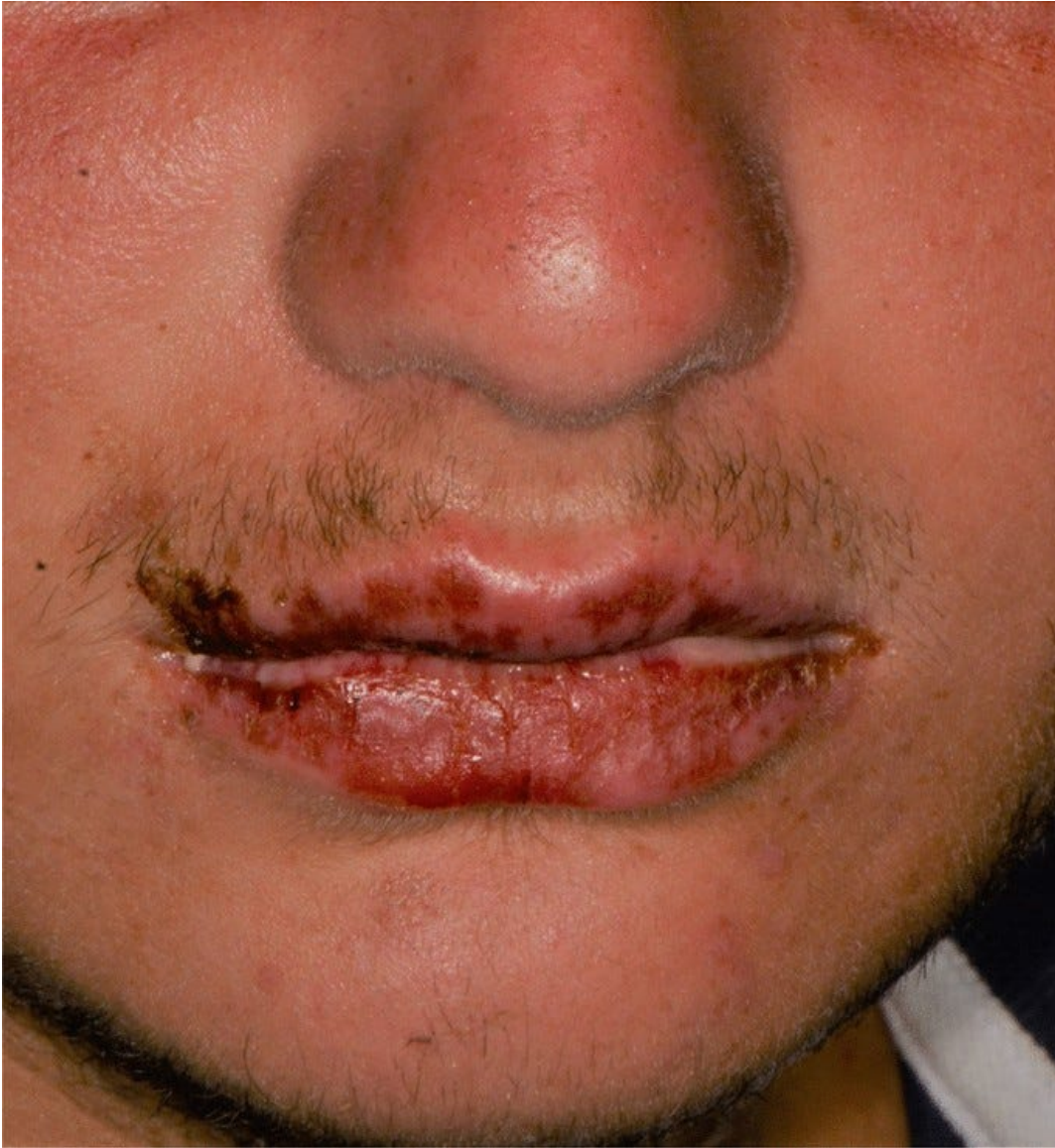

[2022 Mar \(Petruzzi et al\)](#) - Oral erythema multiforme after Pfizer-BioNTech COVID-19 vaccination: a report of four cases

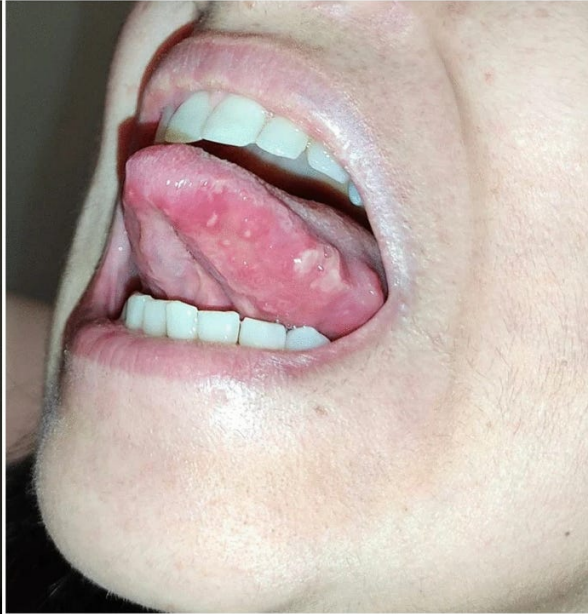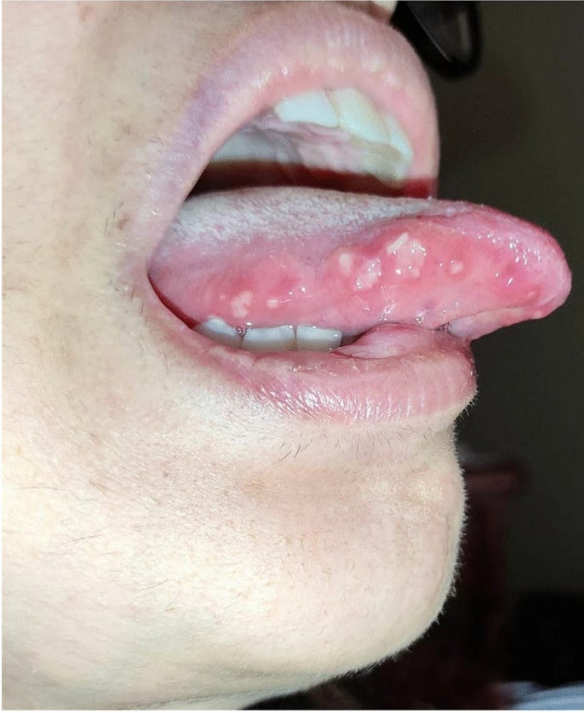- Case Series of 4 cases post Pfizer mRNA Vaccination
- CASE 1: 55F had 1st Pfizer mRNA dose 10 days prior
- presented complaining of painful lesions on lips, oral mucosa, hands, knees, and feet



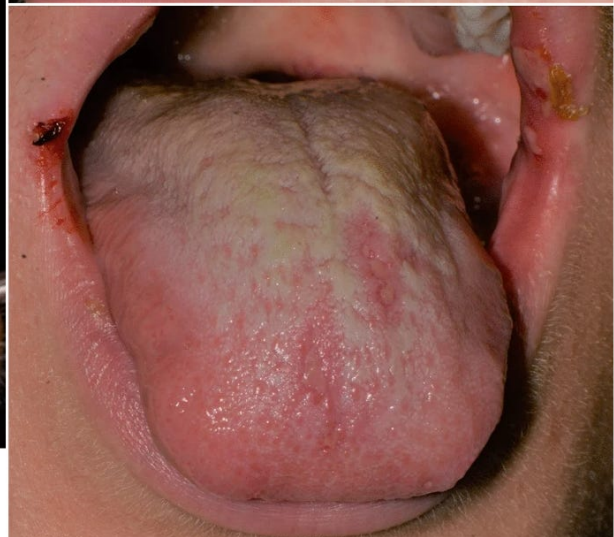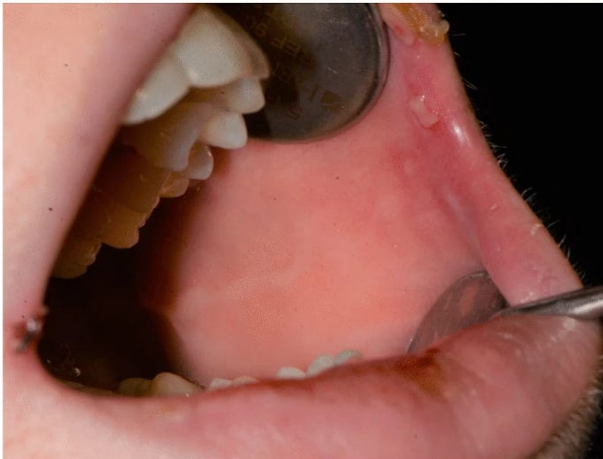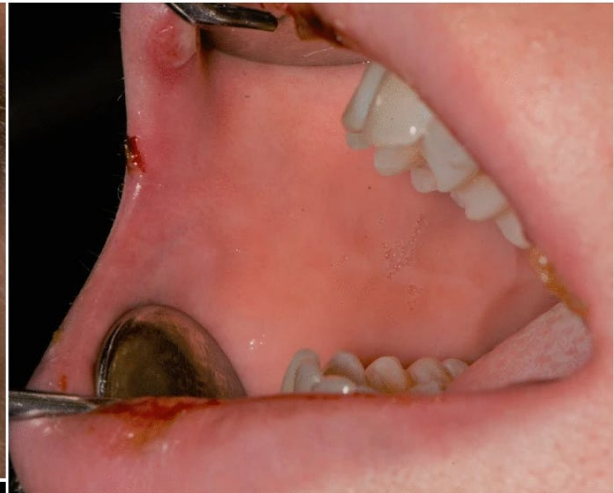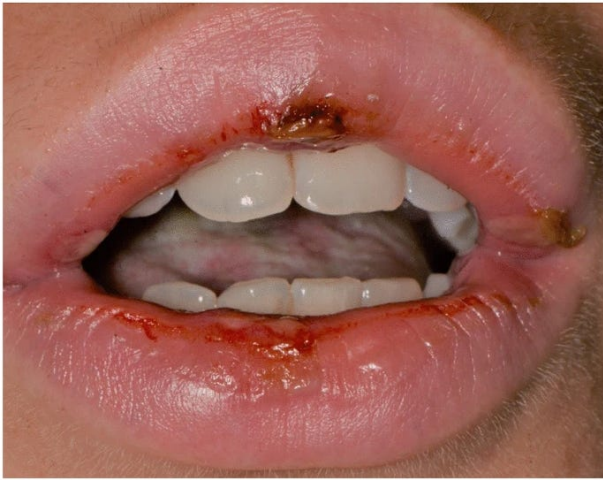- CASE 2: 15M had 1st Pfizer mRNA dose 7 days prior
- developed oral erythema, erosions, and pseudo-membranes throughout the oral mucosa, associated with severe pain and dysphagia



- CASE 3 - 49F had 2nd Pfizer mRNA dose 24 hours prior to onset
- presented with erythematous and bullous like lesions on tongue and mouth floor



- CASE 4: 20F had 1st dose of Pfizer mRNA 18 days prior
- presented with pain and bleeding from the mouth, dysphagia and dysphonia
- P/E: erosions on the gingival and lips mucosa, squamous crusted lesions on the labial skin and vermillion



[2021 Nov \(Burlando et al\)](#) - Cutaneous reactions to COVID-19 vaccine at the dermatology primary care

- 21 patients were referred to Dermatology Clinic with skin reactions after COVID-19 Vaccination
- One patient out of 21 (67 year old man), 48 hours after the second dose of Moderna vaccine, developed a bullous erythema multiforme, which required hospitalization

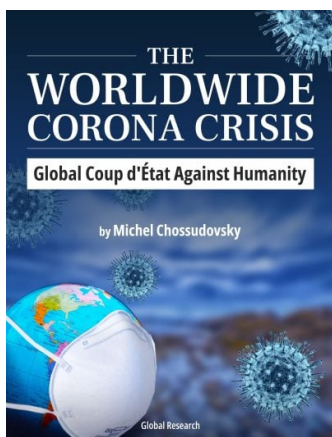
[Click here to read the full article.](#)

*

Note to readers: Please click the share button above. Follow us on Instagram and Twitter and subscribe to our Telegram Channel. Feel free to repost and share widely Global Research articles.

Dr. William Makis is a Canadian physician with expertise in Radiology, Oncology and Immunology. Governor General's Medal, University of Toronto Scholar. Author of 100+ peer-reviewed medical publications.

Featured image is from COVID Intel



The Worldwide Corona Crisis, Global Coup d'Etat Against Humanity

by Michel Chossudovsky

Michel Chossudovsky reviews in detail how this insidious project “destroys people’s lives”. He provides a comprehensive analysis of everything you need to know about the “pandemic” — from the medical dimensions to the economic and social repercussions, political underpinnings, and mental and psychological impacts.

“My objective as an author is to inform people worldwide and refute the official narrative which has been used as a justification to destabilize the economic and social fabric of entire countries, followed by the imposition of the “deadly” COVID-19 “vaccine”. This crisis affects humanity in its entirety: almost 8 billion people. We stand in solidarity with our fellow human beings and our children worldwide. Truth is a powerful instrument.”

Reviews

This is an in-depth resource of great interest if it is the wider perspective you are motivated to understand a little better, the author is very knowledgeable about geopolitics and this comes out in the way Covid is contextualized. —Dr. Mike Yeadon

In this war against humanity in which we find ourselves, in this singular, irregular and massive assault against liberty and the goodness of people, Chossudovsky's book is a rock upon which to sustain our fight. -Dr. Emanuel Garcia

In fifteen concise science-based chapters, Michel traces the false covid pandemic, explaining how a PCR test, producing up to 97% proven false positives, combined with a relentless 24/7 fear campaign, was able to create a worldwide panic-laden "plandemic"; that this plandemic would never have been possible without the infamous DNA-modifying Polymerase Chain Reaction test - which to this day is being pushed on a majority of innocent people who have no clue. His conclusions are evidenced by renown scientists. —Peter Koenig

Professor Chossudovsky exposes the truth that "there is no causal relationship between the virus and economic variables." In other words, it was not COVID-19 but, rather, the deliberate implementation of the illogical, scientifically baseless lockdowns that caused the shutdown of the global economy. -David Skripac

A reading of Chossudovsky's book provides a comprehensive lesson in how there is a global coup d'état under way called "The Great Reset" that if not resisted and defeated by freedom loving people everywhere will result in a dystopian future not yet imagined. Pass on this free gift from Professor Chossudovsky before it's too late. You will not find so much valuable information and analysis in one place. -Edward Curtin

ISBN: 978-0-9879389-3-0, **Year:** 2022, PDF Ebook, **Pages:** 164, 15 Chapters

Price: \$11.50 FREE COPY! [Click here \(docsend\) and download.](#)

We encourage you to support the eBook project by making a donation through Global Research's [DonorBox "Worldwide Corona Crisis" Campaign Page.](#)

The original source of this article is [COVID Intel](#)
Copyright © [Dr. William Makis](#), [COVID Intel](#), 2023

[Comment on Global Research Articles on our Facebook page](#)

[Become a Member of Global Research](#)

Articles by: [Dr. William Makis](#)

Disclaimer: The contents of this article are of sole responsibility of the author(s). The Centre for Research on Globalization will not be responsible for any inaccurate or incorrect statement in this article. The Centre of Research on Globalization grants

permission to cross-post Global Research articles on community internet sites as long the source and copyright are acknowledged together with a hyperlink to the original Global Research article. For publication of Global Research articles in print or other forms including commercial internet sites, contact: publications@globalresearch.ca

www.globalresearch.ca contains copyrighted material the use of which has not always been specifically authorized by the copyright owner. We are making such material available to our readers under the provisions of "fair use" in an effort to advance a better understanding of political, economic and social issues. The material on this site is distributed without profit to those who have expressed a prior interest in receiving it for research and educational purposes. If you wish to use copyrighted material for purposes other than "fair use" you must request permission from the copyright owner.

For media inquiries: publications@globalresearch.ca