

# Children COVID mRNA Vaccine-Injured: Encephalitis After Pfizer COVID-19 mRNA Vaccine. Potentially Deadly Brain Inflammation

33 cases (personality changes, seizures, hallucinations) - 3 deaths, 4 disabled

By [Dr. William Makis](#)

Theme: [Science and Medicine](#)

Global Research, November 24, 2023

[COVID Intel](#)

All Global Research articles can be read in 51 languages by activating the Translate Website button below the author's name.

To receive Global Research's Daily Newsletter (selected articles), [click here](#).

Click the share button above to email/forward this article to your friends and colleagues. Follow us on [Instagram](#) and [Twitter](#) and subscribe to our [Telegram Channel](#). Feel free to repost and share widely Global Research articles.

\*\*\*

*March 3, 2022 - Brazil - 15 year old Danylo Zinneck Nobre was perfectly healthy. He had his 1st Pfizer mRNA Vaccine on Aug. 24, 2021 and second on Oct. 19, 2021. Here is his story:*

[He took 2 doses of Pfizer](#), the first on Aug.24, 2021 and the second on Oct.19, 2021.

Eighteen days later he had some slight fatigue. Then weakness in the legs. And then he began to experience blurred vision and heaviness in the head.

Then on Jan.6, 2022, he had a seizure and was intubated with difficulty swallowing and slurred speech.

He was taken to Hospital. There, an examination was performed without the presence of bacteria or virus. He had normal MRI, and he had several CT scans all with nothing abnormal.

He had daily labs, all normal.

He was left with paralysis in the diaphragm and upper and lower limbs, and had a tracheostomy.

He was diagnosed with Autoimmune Bickerstaff Brainstem Encephalitis (BBE), a rare neurological disease that affects the central nervous system and peripheral.

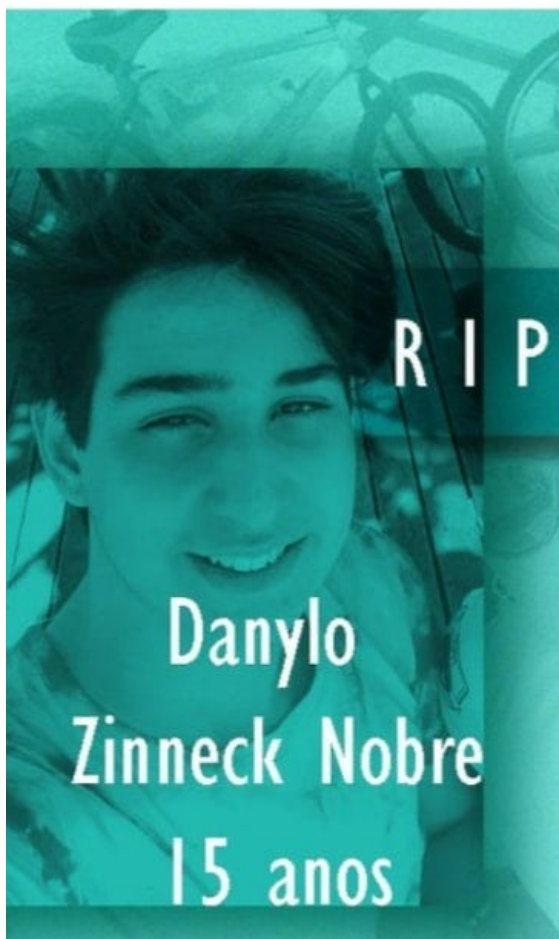
He underwent plasmapheresis treatment, a procedure aimed at filtering the blood, removing the substances that are causing damage from the plasma.

However, in the 5th session he suffered a hemorrhagic stroke, which was reabsorbed 80%, and an EVD lead was placed.

When changing the EVD, however, there was bleeding followed by brain death.

“My son was totally healthy, he had never been sick, he didn’t even know what a fever was. I stayed with him for 2 months in an ICU room until he died on Mar. 3, 2022.”

\_injuries\_brasil\_

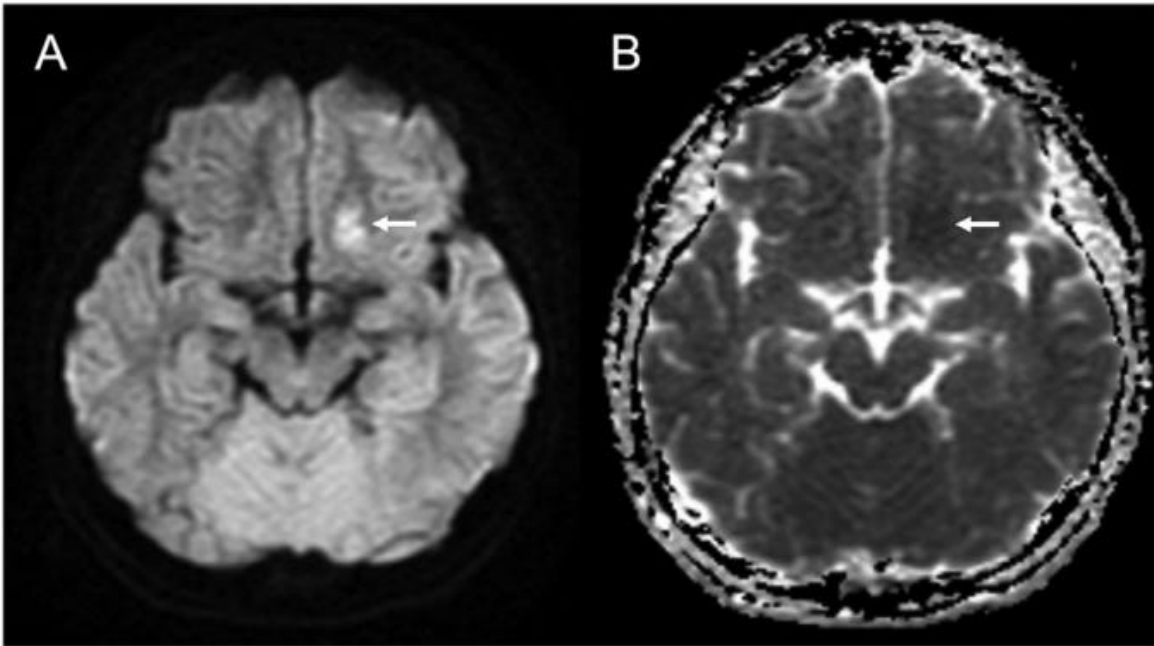


"Meu amado filho Danylo Zinneck Nobre, 15 anos, de São Sebastião/SP, tomou 2 doses de Pfz em 24/08/2021 e 19/10/2021. Dezoito dias depois apresentou leve fadiga. Depois, fraqueza nas pernas. Então, começou a sentir a visão turva e sensação de peso na cabeça. Em 06/01/2022, teve uma convulsão e foi entubado com dificuldade de deglutição e fala enrolada. Em menos de 1 hora descontrole total: o tronco encefálico atingiu o bulbo responsável pela deglutição e parte motora. Foi transferido para São José dos Campos, para o Hospital Municipal Florence. Lá, foi feito exame de líquor sem presença de bactéria ou vírus. Ressonância normal, diversas tomografias e nada de anormalidade. Exames biomédicos diários PCR, todos normais. Ficou com paralisia no diafragma e nos membros superiores e inferiores, e foi traqueostomizado. Foi diagnosticado com Encefalite do tronco cerebral de Bickerstaff autoimune (BBE), uma doença neurológica rara, que afeta o sistema nervoso central e periférico. Fez tratamento de plasmaférese, procedimento com objetivo de filtrar o sangue, retirando do plasma as substâncias que estão causando dano. Porém, na quinta sessão sofreu um AVC hemorrágico, que foi reabsorvido 80%, e colocada uma derivação DVE. Ao fazer a troca do DVE, porém, houve sangramento e morte encefálica. Meu filho era totalmente sadio, nunca havia adoecido, não sabia nem que era febre. Depois do ocorrido, fiquei com ele 2 meses em uma sala de UTI, numa linha tênue cheia de sobressaltos. O óbito foi em 03/03/2022."

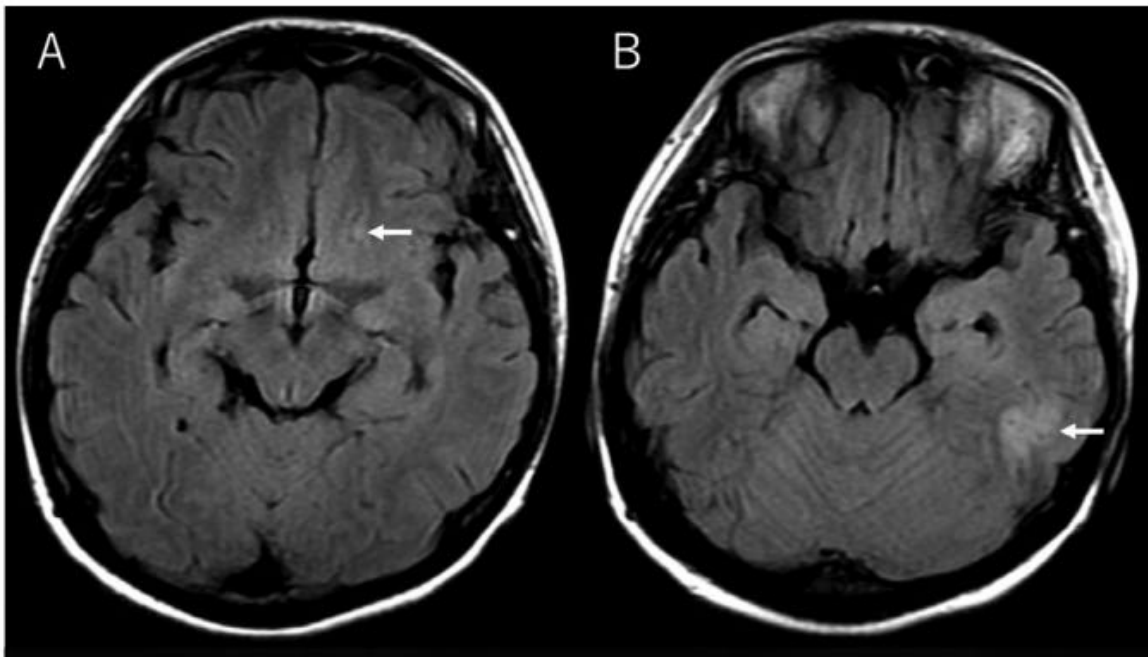
**DANYLO**  
DANYLO ZINNECK NOBRE, 15 ANOS  
EM 24/AGOSTO/2021  
E 19/OUTUBRO/2021  
EM 03/MARÇO/2022  
**PFIZER ÓBITO**  
APÓS 18 DIAS DA SEGUNDA DOSE, COMEÇOU A SENTIR FADIGA, FRAQUEZA. DEPOIS, VISÃO TURVA. NO INÍCIO DE JANEIRO, SOFREU UMA CONVULSÃO, TEVE QUE SER ENTUBADO, COM DIFICULDADE DE DEGLUTIÇÃO, PARALISIA NOS MEMBROS SUPERIORES E INFERIORES E NO DÍFRAGMA. FEZ TRATAMENTO DE PLASMAFERESE, PORÉM SOFREU UM AVC HEMORRÁGICO, E POR FIM, MORTE ENCEFÁLICA.  
**ENCEFALITE AUTOIMUNE**  
Para reportar seu caso escreva para: [oscasosraros@gmail.com](mailto:oscasosraros@gmail.com) / Instagram: [@0scasosraros](https://www.instagram.com/0scasosraros) / Telegram: [OsCasosRaros](https://www.telegram.com/OsCasosRaros)

[2023 April \(Masato Ando et al\)](#) – Autoantibody-negative but probable pediatric autoimmune encephalitis following COVID-19 vaccination: A case report

- 14 year old Japanese girl had 3rd Pfizer COVID-19 mRNA Vaccine
- 19 days later she presented to ER because of a seizure
- She had a headache and fever 5 days before the seizure, followed by diarrhea
- She gradually became apathetic and developed mutism the day before presentation.
- in ER, she was 37.4C, HR 130 bpm, respiratory rate 26 bpm, stiff neck, positive Kernig’s sign.
- By the time she was admitted to pediatric ward she couldn’t speak words or follow instructions!
- MRI showed multiple areas of brain inflammation
- She was diagnosed with autoimmune encephalitis but no antibodies were found
- Treatment: she was started on steroid pulse therapy with 3-day IV methylprednisolone at 1g per day.
- She returned to her normal self soon after the 2nd dose.



**Fig. 1.** Brain MRI on the day of admission. (A) DWI shows hyperintensity in the cortex along the left olfactory sulcus. (B) Apparent diffusion coefficient (ADC) maps present reduced diffusivity in the corresponding area.



2023 Sep. 6 EMA (European Medicines Agency) Report - Girl 12-17 years old had 1st Pfizer mRNA COVID-19 Vaccine and developed Encephalitis of the brainstem and was paralyzed and disabled.

General Information	
EudraVigilance Local Report Number	EU-EC-10015347059
Sender Type	Regulatory authority
Sender's Organisation	EEA Regulator
Type of Report	Spontaneous
Primary source country	European Economic Area
Reporter's qualification	Healthcare Professional
Case serious?	Yes

Patient		
Age Group	Age Group (as per reporter)	Sex
12-17 Years	Adolescent	Female

Reaction / Event			
MedDRA LLT	Duration	Outcome	Seriousness <sup>1</sup>
Demyelinating disease (excl multiple sclerosis)		Recovering/Resolving	hospital., disability
Dizziness		Recovered/Resolved	hospital., disability
Tiredness		Unknown	hospital., disability
Fever		Recovered/Resolved	hospital., disability
Facial paresis		Recovered/Resolved	hospital., disability
Cerebral thrombosis		Recovered/Resolved With Sequelae	hospital., disability
Encephalitis brain stem		Recovering/Resolving	hospital., disability
Ischaemia cerebrovascular		Recovered/Resolved With Sequelae	hospital., disability
Vaccination site tenderness		Unknown	hospital., disability
Numbness in face		Unknown	hospital., disability
Headache		Recovered/Resolved	hospital., disability
Paralysis		Not Recovered/Not Resolved	hospital., disability

Drug Information					
Role <sup>2</sup>	Drug	Duration	Dose	Units in Interval	Action taken
S	COMIRNATY - TOZINAMERAN		1.0 (DF)		Unknown

**Adverse Reports**  
@AdverseReports

This young girl left disabled after the #Pfizer #mRNA tozinameran vaccine  
Ischaemia cerebrovascular  
Encephalitis brain stem  
Cerebral thrombosis  
Paralysis  
09/06/23  
[adreports.eu/en/index.html](https://adreports.eu/en/index.html)

2:11 AM · Jul 15, 2023 · 602 Views

🗨️ 1 🔄 15 ❤️ 16 📌 1 📤

🌟 See similar posts →

[2023 May 21 \(VAERS 2646388\)](#) – 10 year old boy (Georgia) had 2nd Pfizer mRNA vaccine on Jan. 25, 2023. In February he started to complain about random headaches. In May 2023 he developed seizures, personality changes, auditory and visual hallucinations.

## Case Details

**VAERS ID:** [2646388](#) (history)    **Vaccinated:** 2023-01-25  
**Form:** Version 2.0    **Onset:** 2023-05-21  
**Age:** 10.0    **Days after vaccination:** 116  
**Sex:** Male    **Submitted:** 0000-00-00  
**Location:** Georgia    **Entered:** 2023-06-16

Vaccination / Manufacturer	Lot / Dose	Site / Route
COVID19: COVID19 (COVID19 (PFIZER-BIONTECH)) / PFIZER/BIONTECH	GD1857 / 2	LA / IM

**Administered by:** Public    **Purchased by:** ?

**Symptoms:** [Blood test](#), [Electroencephalogram](#), [Encephalitis autoimmune](#), [Hallucination, auditory](#), [Hallucination, visual](#), [Headache](#), [Lumbar puncture](#), [Magnetic resonance imaging head](#), [Personality change](#), [Pyrexia](#), [Seizure](#), [Ultrasound testes](#)

**SMQs:** Torsade de pointes/QT prolongation (broad), Neuroleptic malignant syndrome (broad), Systemic lupus erythematosus (broad), Anticholinergic syndrome (broad), Dementia (broad), Convulsions (narrow), Psychosis and psychotic disorders (narrow), Noninfectious encephalitis (narrow), Noninfectious encephalopathy/delirium (broad), Noninfectious meningitis (broad), Hostility/aggression (broad), Generalised convulsive seizures following immunisation (narrow), Drug reaction with eosinophilia and systemic symptoms syndrome (broad), Hypoglycaemia (broad), Immune-mediated/autoimmune disorders (narrow)

**Life Threatening?** No

**Birth Defect?** No

**Died?** No

**Permanent Disability?** No

**Recovered?** No

**Office Visit?** No

**ER Visit?** No

**ER or Doctor Visit?** No

**Hospitalized?** Yes, 13 days

**Extended hospital stay?** No

**Previous Vaccinations:**

**Other Medications:** None

**Current Illness:** None

**Preexisting Conditions:** None

**Allergies:** None

**Diagnostic Lab Data:** MRI brain, extensive blood work, EEG, lumbar puncture, testicular u/s

**CDC Split Type:**

**Write-up:** Mom notes that in February he started to complain about random headaches and had never had headaches before. In March 2023 he had a high fever and HA of unknown cause. Sx resolved. In May 2023 he had high fever and HA of unknown cause that then progressed to seizures and a working diagnosis of autoimmune encephalitis. He has had seizures, personality changes, auditory and visual hallucinations. Mom feels like symptoms began after the covid vaccination series, severe sx didn't start until about 5 months following the vaccination

[2022 May 25 \(VAERS 2505252\)](#) - 14 year old previously healthy boy (California) had 3rd Pfizer mRNA Vaccine on March 18, 2022. 2 months later was hospitalized with encephalitis starting on May 25, 2022 until June 16, 2022. "Has a long road to recovery". Was in ICU for 2 weeks, had to live in rehab for 2 weeks. Can only attend one class in high school.

## Case Details

**VAERS ID:** [2505252](#) (history)    **Vaccinated:** 2022-03-18  
**Form:** Version 2.0    **Onset:** 2022-05-25  
**Age:** 14.0    **Days after vaccination:** 68  
**Sex:** Male    **Submitted:** 0000-00-00  
**Location:** California    **Entered:** 2022-11-11

Vaccination / Manufacturer	Lot / Dose	Site / Route
COVID19: COVID19 (COVID19 (PFIZER-BIONTECH)) / PFIZER/BIONTECH	FK9729 / 3	LA / -

**Administered by:** Unknown    **Purchased by:** ?

**Symptoms:** [Chest X-ray](#), [Electroencephalogram](#), [Encephalitis](#), [Magnetic resonance imaging](#)  
**SMQs:** Noninfectious encephalitis (narrow), Drug reaction with eosinophilia and systemic symptoms syndrome (broad), Immune-mediated/autoimmune disorders (broad)

**Life Threatening?** No

**Birth Defect?** No

**Died?** No

**Permanent Disability?** No

**Recovered?** No

**Office Visit?** No

**ER Visit?** No

**ER or Doctor Visit?** No

**Hospitalized?** Yes, ? days

**Extended hospital stay?** No

**Previous Vaccinations:**

**Other Medications:**

**Current Illness:**

**Preexisting Conditions:** Medical History/Concurrent Conditions: Cold (cold and flus like every other kid); Flu (cold and flus like every other kid)

**Allergies:**

**Diagnostic Lab Data:** Test Name: Chest X-ray; Result Unstructured Data: Test Result:Unknown results; Test Name: EEG; Result Unstructured Data: Test Result:Unknown results; Test Name: MRI; Result Unstructured Data: Test Result:Unknown results

**CDC Split Type:** USPFIZER INC202201282840

**Write-up:** encephalitis; This is a spontaneous report received from a contactable reporter (Consumer) from medical information team, Program ID: (Unknown). The reporter is the parent. A 14-year-old male patient received BNT162b2 (COMIRNATY), on 18Mar2022 as dose 3 (booster), single (Lot number: FK9729) at the age of 14 years, in left deltoid (reported as left shoulder) for covid-19 immunisation. The patient's relevant medical history included: "Cold" (unspecified if ongoing); "flus" (unspecified if ongoing). The patient was prior a healthy kid, has never been sick and was never in the hospital except for her giving birth to him. He had the cold and flus like every other kid. He was lean and not overweight and no medical history whatsoever (as reported). He is a server and an avid swimmer, on the swim team and a surfer; the specialists can't tell what cause it. There were no concomitant medications. Vaccination history included: BNT162b2 (DOSE 1, Lot: EW0196, Anatomical Location: Left upper arm shoulder), administration date: 09Jul2021, when the patient was 13-year-old, for COVID-19 immunization; BNT162b2 (DOSE 2, Lot: FA7485, Anatomical location: Left upper shoulder), administration date: 09Aug2021, when the patient was 13-year-old, for COVID-19 Immunization. The following information was reported: ENCEPHALITIS (hospitalization) with onset 25May2022, outcome "recovering". The patient was hospitalized for encephalitis (start date: 24May2022, discharge date: Jun2022). Also reported that he was at the hospital from 25May2022 to 16Jun2022 or 17Jun2022. After his booster he was hospitalized with encephalitis. The patient got all three shots from Pfizer. The first two normal vaccinations and then he was vaccinated with the bivalent (as reported) booster dose maybe a month (as reported) before he got encephalitis. The patient underwent the following laboratory tests and procedures: Chest X-ray: Unknown results; Electroencephalogram: Unknown results; Magnetic resonance imaging: Unknown results. Outcome was reported as improving. He does have the infection anymore (as reported) and he has a long road to recovery. Treatment indicated that the patient was in the ICU for two weeks and home for a week and a half and had to live in rehab for 2 weeks. Now, he was home, and he has so much therapy and he is supposed to be a freshmen in high school and only attends one class.

[2021 Dec. 06 \(VAERS 1948381\)](#) - 11 year old boy (Texas) had 1st Pfizer mRNA and Flu Vaccine (Quadrivalent GlaxoSmithKline Biologicals) on Nov. 17, 2021. 19 days later, on Dec. 6, he developed severe headaches and somnolence for 7 days. MRI came back as acute disseminated encephalomyelitis and he was started on high dose steroids.

## Case Details

**VAERS ID:** [1948381](#) (history)      **Vaccinated:** 2021-11-17  
**Form:** Version 2.0      **Onset:** 2021-12-06  
**Age:** 11.0      **Days after vaccination:** 19  
**Sex:** Male      **Submitted:** 0000-00-00  
**Location:** Texas      **Entered:** 2021-12-14

Vaccination / Manufacturer	Lot / Dose	Site / Route
COVID19: COVID19 (COVID19 (PFIZER-BIONTECH)) / PFIZER/BIONTECH	FK5127 / 1	RA / IM
FLU4: INFLUENZA (SEASONAL) (FLULAVAL QUADRIVALENT) / GLAXOSMITHKLINE BIOLOGICALS	2493G / 1	RA / IM

**Administered by:** Military      **Purchased by:** ?

**Symptoms:** [Acute disseminated encephalomyelitis](#), [Headache](#), [Magnetic resonance imaging abnormal](#), [Somnolence](#), [White matter lesion](#)

**SMQs:** Anticholinergic syndrome (broad), Dementia (broad), Noninfectious encephalitis (narrow), Noninfectious encephalopathy/delirium (broad), Noninfectious meningitis (broad), Demyelination (narrow), Hypoglycaemia (broad)

**Life Threatening?** No

**Birth Defect?** No

**Died?** No

**Permanent Disability?** No

**Recovered?** No

**Office Visit?** No

**ER Visit?** No

**ER or Doctor Visit?** No

**Hospitalized?** Yes, 5 days

**Extended hospital stay?** No

**Previous Vaccinations:**

**Other Medications:** none

**Current Illness:** No other illnesses

**Preexisting Conditions:** None

**Allergies:** none

**Diagnostic Lab Data:** MRI FLAIR/T2 with abnormalities throughout the bilateral cortices and juxtacortical white matter without significant post contrast enhancement.

**CDC Split Type:**

**Write-up:** Covid19 and Flu vaccine were given on Nov 17,2021. [On Dec 6th patient started to endorse severe headaches that waxed and waned for 7 days and somnolence . On Dec 13 was admitted after MRI confirmed signs of acute disseminated encephalomyelitis.](#) Patient was started on high dose steroids for at least 5 days inpatient with steroid taper following.

[2021 Nov. 20 \(VAERS 2325596\)](#) - 6 year old girl (Illinois) had 1st Pfizer mRNA on Nov.18, 2021. Two days later, she developed whole body hives and joint pain. After seeing many specialists, she was eventually diagnosed with Autoimmune encephalitis.



**VAERS ID:** [2325596](#) (history)    **Vaccinated:** 2021-11-18  
**Form:** Version 2.0    **Onset:** 2021-11-20  
**Age:** 6.0    **Days after vaccination:** 2  
**Sex:** Female    **Submitted:** 0000-00-00  
**Location:** Illinois    **Entered:** 2022-06-21

Vaccination / Manufacturer	Lot / Dose	Site / Route
COVID19: COVID19 (COVID19 (PFIZER-BIONTECH)) / PFIZER/BIONTECH	FK5127 / 1	LA / IM

**Administered by:** Private    **Purchased by:** ?  
**Symptoms:** [Allergy test negative](#), [Arthralgia](#), [Blood test abnormal](#), [Complement factor C3 increased](#), [Complement factor C4 increased](#), [Cyst](#), [Electroencephalogram abnormal](#), [Encephalitis autoimmune](#), [Immunoglobulins decreased](#), [Magnetic resonance imaging normal](#), [Obsessive-compulsive symptom](#), [Serum sickness-like reaction](#), [Skin test negative](#), [Urticaria](#)  
**SMQs:** Anaphylactic reaction (broad), Angioedema (narrow), Noninfectious encephalitis (narrow), Noninfectious encephalopathy/delirium (broad), Hypersensitivity (narrow), Arthritis (broad), Tendinopathies and ligament disorders (broad), Drug reaction with eosinophilia and systemic symptoms syndrome (broad), Immune-mediated/autoimmune disorders (narrow)  
**Life Threatening?** No  
**Birth Defect?** No  
**Died?** No  
**Permanent Disability?** No  
**Recovered?** No  
**Office Visit?** Yes  
**ER Visit?** No  
**ER or Doctor Visit?** Yes  
**Hospitalized?** No  
**Previous Vaccinations:**  
**Other Medications:** None  
**Current Illness:** Asthma, eczema, history of brain bleed at birth  
**Preexisting Conditions:** Asthma, eczema, history of brain bleed at birth  
**Allergies:** None know  
**Diagnostic Lab Data:** Allergy skin prick test to rule out allergy to vaccine- negative. MRI and EEG- no signs of seizures present, incidental cysts found otherwise unremarkable. Blood tests showing low immunoglobulins and high C3, C4.  
**CDC Split Type:**  
**Write-up:** Serum sickness like reaction with whole body hives and joint pain. Seen in ER. Treated with oral prednisone and then seen by immunologist on outpatient basis. Confirmed not an allergic reaction but [hyper immune response](#). [OCD symptoms and autoimmune encephalitis \(PANS\) diagnosed after seeing psychiatrist, neurologist, rheumatologist, immunologist, therapists.](#)

[2021 Oct 31 \(VAERS 1853455\)](#) - 13 year old boy had Pfizer mRNA Vaccine on Oct. 1, 2021. 1 month later on Oct. 31, 2021 he was diagnosed with Transverse Myelitis and Encephalitis.

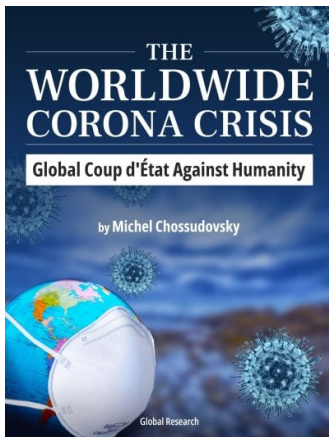
[Click here to read the full article.](#)

\*

Note to readers: Please click the share button above. Follow us on Instagram and Twitter and subscribe to our Telegram Channel. Feel free to repost and share widely Global Research articles.

*Dr. William Makis is a Canadian physician with expertise in Radiology, Oncology and Immunology. Governor General's Medal, University of Toronto Scholar. Author of 100+ peer-reviewed medical publications.*

*Featured image is from COVID Intel*



## The Worldwide Corona Crisis, Global Coup d'Etat Against Humanity

by Michel Chossudovsky

Michel Chossudovsky reviews in detail how this insidious project “destroys people’s lives”. He provides a comprehensive analysis of everything you need to know about the “pandemic” — from the medical dimensions to the economic and social repercussions, political underpinnings, and mental and psychological impacts.

*“My objective as an author is to inform people worldwide and refute the official narrative which has been used as a justification to destabilize the economic and social fabric of entire countries, followed by the imposition of the “deadly” COVID-19 “vaccine”. This crisis affects humanity in its entirety: almost 8 billion people. We stand in solidarity with our fellow human beings and our children worldwide. Truth is a powerful instrument.”*

### Reviews

*This is an in-depth resource of great interest if it is the wider perspective you are motivated to understand a little better, the author is very knowledgeable about geopolitics and this comes out in the way Covid is contextualized. —Dr. Mike Yeadon*

*In this war against humanity in which we find ourselves, in this singular, irregular and massive assault against liberty and the goodness of people, Chossudovsky’s book is a rock upon which to sustain our fight. —Dr. Emanuel Garcia*

*In fifteen concise science-based chapters, Michel traces the false covid pandemic, explaining how a PCR test, producing up to 97% proven false positives, combined with a relentless 24/7 fear campaign, was able to create a worldwide panic-laden “plandemic”; that this plandemic would never have been possible without the infamous DNA-modifying Polymerase Chain Reaction test - which to this day is being pushed on a majority of innocent people who have no clue. His conclusions are evidenced by renown scientists. —Peter Koenig*

*Professor Chossudovsky exposes the truth that “there is no causal relationship between the virus and economic variables.” In other words, it was not COVID-19 but, rather, the deliberate implementation of the illogical, scientifically baseless lockdowns that caused the shutdown of the global economy. —David Skripac*

*A reading of Chossudovsky’s book provides a comprehensive lesson in how there is a global coup d’état under way called “The Great Reset” that if not resisted and defeated by freedom*

*loving people everywhere will result in a dystopian future not yet imagined. Pass on this free gift from Professor Chossudovsky before it's too late. You will not find so much valuable information and analysis in one place. -Edward Curtin*

ISBN: 978-0-9879389-3-0, Year: 2022, PDF Ebook, Pages: 164, 15 Chapters

Price: ~~\$11.50~~ FREE COPY! [Click here \(docsend\) and download.](#)

We encourage you to support the eBook project by making a donation through Global Research's [DonorBox "Worldwide Corona Crisis" Campaign Page.](#)

The original source of this article is [COVID Intel](#)  
Copyright © [Dr. William Makis](#), [COVID Intel](#), 2023

---

[Comment on Global Research Articles on our Facebook page](#)

[Become a Member of Global Research](#)

Articles by: [Dr. William Makis](#)

**Disclaimer:** The contents of this article are of sole responsibility of the author(s). The Centre for Research on Globalization will not be responsible for any inaccurate or incorrect statement in this article. The Centre of Research on Globalization grants permission to cross-post Global Research articles on community internet sites as long the source and copyright are acknowledged together with a hyperlink to the original Global Research article. For publication of Global Research articles in print or other forms including commercial internet sites, contact: [publications@globalresearch.ca](mailto:publications@globalresearch.ca)  
[www.globalresearch.ca](http://www.globalresearch.ca) contains copyrighted material the use of which has not always been specifically authorized by the copyright owner. We are making such material available to our readers under the provisions of "fair use" in an effort to advance a better understanding of political, economic and social issues. The material on this site is distributed without profit to those who have expressed a prior interest in receiving it for research and educational purposes. If you wish to use copyrighted material for purposes other than "fair use" you must request permission from the copyright owner.

For media inquiries: [publications@globalresearch.ca](mailto:publications@globalresearch.ca)